

and cerebral perfusion continued through the right CCA graft. The left CCA was then anastomosed end-to-end to a branch of the soft graft to re-establish bilateral cerebral perfusion. The proximal soft graft was then anastomosed end-to-end to the original root graft. Tricuspid ring valvuloplasty was performed (30-mm AnnuloFlex ring; Carbomedics) with the heart still arrested. While rewarming, the innominate artery anastomosis was created end-to-end to the remaining limb of the branched graft. After de-airing and rewarming, the patient was successfully weaned from the bypass circuit.

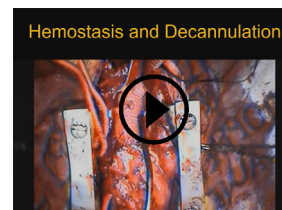DISCUSSION

LDS is a recently described genetic syndrome characterized by triad of arterial tortuosity and aneurysms, hypertelorism, and bifid uvula or cleft palate that results from mutations in receptors for the cytokine transforming growth factor- β .² With growing experience, it has been recognized as an aggressive connective tissue disorder with increased risk of aortic dissection and aneurysm rupture at an early age and smaller aortic diameters.^{3,4} Understanding of the natural history of this disease continues to evolve. Total aortic replacement is necessary in about one-fifth of patients with LDS who require intervention.⁴ Valve-sparing root replacement has gained traction in this population,³ but management of arch disease is still evolving. In this case, the patient had a valve-sparing root and ascending/hemiarch replacement at a very young age (11 months). This repair proved durable, lasting through age 12 years while the remaining native transverse arch continued to degenerate. In planning for this operation, ACP was employed through the carotid artery to facilitate adequate time with circulatory arrest and to secure a site for arterial cannulation in the event of injury during redo sternotomy. The use of stented grafts in the pediatric population certainly has its drawbacks given the rapidly expanding nature of aortic dilation and concern for later failure.⁵ To get the most proximal landing zone possible and minimize stent extension into the arch,

the left carotid-subclavian transposition was performed through the left neck. However, this case illustrates how aggressive the disease can be. Patients can present as early as age 3 months,³ so the treatment paradigm needs a more well-rounded approach that incorporates cardiovascular surgeons who treat children as well as adults. The need for thoracoabdominal repair is not well defined but of patients with LDS requiring surgery, between 4% and 12% require thoracoabdominal repair.^{4,5} This patient went on to require extent 3 thoracoabdominal repair 3 years later after presenting with a type B dissection beyond his repair. In this case, having the hybrid repair facilitated the subsequent thoracoabdominal approach.

Webcast

You can watch a Webcast of this AATS meeting presentation by going to: <https://www.aats.org/resources/1605>.



References

1. Eldeiry M, Aftab M, Bergeron E, Pal J, Cleveland JC Jr, Fullerton D. The buffalo trunk technique for aortic arch reconstruction. *Ann Thorac Surg.* 2019;108:680-6.
2. Loeys BL, Schwarze U, Holm T, Callewaert BL, Thomas GH, Pannu H, et al. Aneurysm syndromes caused by mutations in the TGF- β receptor. *N Engl J Med.* 2006;355:788-98.
3. Williams JA, Loeys BL, Nwakanma LU, Dietz HC, Spevak PJ, Patel ND, et al. Early surgical experience with Loeys-Dietz: a new syndrome of aggressive thoracic aortic aneurysm disease. *Ann Thorac Surg.* 2007;83(2 Suppl):S757-63.
4. Aftab M, Cikach FS, Zhu Y, Idrees JJ, Rigelsky CM, Kalahasti V, et al. Loeys-Dietz syndrome: intermediate-term outcomes of medically and surgically managed patients. *J Thorac Cardiovasc Surg.* 2019;157:439-50.
5. Patel ND, Crawford T, Magruder JT, Alejo DE, Hibino N, Black J, et al. Cardiovascular operations for Loeys-Dietz syndrome: intermediate-term results. *J Thorac Cardiovasc Surg.* 2017;153:406-12.

Discussion

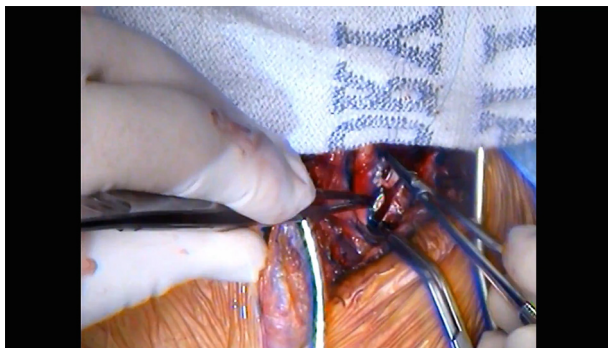
Presenter: Mohamed Eldeiry

Unidentified Speaker 1. Very nice case. Very well planned and executed. Our discuss is Dr Duke Cameron from Mass General.



Dr Duke Cameron (Boston, Mass).

Thank you very much. This was a really spectacular outcome and a complex and challenging case, which demonstrates just how aggressive this aortopathy is. It's probably the most virulent of all of the aortopathies that we see in children, and as you pointed out, the problem is these vessels will



VIDEO 1. This video outlines the surgical details of the case presented. Video available at: [https://www.jtcvs.org/article/S2666-2507\(22\)00465-5/fulltext](https://www.jtcvs.org/article/S2666-2507(22)00465-5/fulltext).

dissect at much smaller diameters much earlier ages compared with other connective tissue disorders. You also mentioned nicely that this disease was described in 2005, so we really only have about 17 years of experience with a very rare disease and we're still learning about the natural history, and we're also learning that the spectrum of this disease is quite broad. This is the most severe form presenting in infancy—really with a massive aneurysm, but we have some patients who don't present until they're 60. So, there's a lot still to learn, and we're going to have to tailor our management of these. I also want to point out again what a beautiful result you had with valve-sparing surgery at 11 months of age. There are still people writing that valve sparing is inappropriate for Loeyz-Dietz syndrome because the results are so bad, and they aren't bad. They're actually good and comparable to Marfan syndrome as long as you do it the way you did it, as a reimplantation. If you try a remodeling-type operation, the annulus is unstable, and they won't hold up well. So, congratulations. Really remarkable that you had an operation in this group of patients that was durable out to over 10 years.

So, I have 3 questions. The first has to do with the rationale for a stented graft in the descending aorta which wasn't that dilated, and the results of stent grafts in Loeyz-Dietz are really disappointing, so were you doing it to prevent aneurysm or facilitate likely future operations? So, enlighten me on that. The second is not so much a question as just to ask you to tell us a little more about the operation that followed this 1, the thoracoabdominal. How did you cannulate? How was your use of circulatory support? And I think you just answered the question, it was actually for dissection, but I'd really like to know how you did that operation and how you managed the stent graft without clamping it, for instance. And the last question—and I apologize for not forewarning you about this—I know what the buffalo operation is, but I've never

understood why you call it a buffalo operation, so maybe you could set us straight on that. And again, congratulations on the outcome.



Dr Mohamed Eldeiry (*Aurora, Colo*).

Fair enough. Thank you so much, Dr Cameron, for your comments. So, in relation to the first question, this patient's vertebral tortuosity, which is one of the index markers of the aggressive nature of this disease, is 200. As you alluded to, we're continuing to understand how this disease manifests. There's almost 2 population paradigms with the adult and younger population in the younger populations, a vertebral tortuosity index in excess of 50 is usually more suggestive of aggressive disease. His was in excess of 200. So going into this operation, we were anticipating that he'll probably need distal repair later on, and that's why we went ahead with the stent graft to hopefully facilitate repair later on. We certainly didn't anticipate that we'd need it 2.5 years later, that soon, but certainly it did come in handy. As far as the thoracoabdominal repair, so we approached it with a standard thoracoabdominal incision. We did dissect the inferior vena cava and the aorta through the chest and cannulated both of them, went on bypass, and then we did crossclamp proximally and distally just before the celiac. And when we did fashion the proximal anastomosis, it was directly to the stent, which provided a more stable structure. For the buffalo trunk, so as you all know, we're from University of Colorado and our mascot is the buffalo. This is the frozen elephant trunk, our hybrid version of the buffalo trunk. We've shown some data on doing the distal anastomosis more efficiently without the actual commercialized hybrid stent graft, so that's why we it the buffalo trunk.

Unidentified Speaker 1. Great. Thank you. Thank you very much.